

Ophthalmic Technology Assessment

Aqueous Shunts in Glaucoma

A Report by the American Academy of Ophthalmology

Don S. Minckler, MD, MS, Brian A. Francis, MD, Elizabeth A. Hodapp, MD,
Henry D. Jampel, MD, MHS, Shan C. Lin, MD, John R. Samples, MD, Scott D. Smith, MD, MPH,
Kuldev Singh, MD, MPH

Objective: To provide an evidence-based summary of commercially available aqueous shunts currently used in substantial numbers (Ahmed [New World Medical, Inc., Rancho Cucamonga, CA], Baerveldt [Advanced Medical Optics, Inc., Santa Ana, CA], Krupin [Eagle Vision, Inc, Memphis, TN], Molteno [Molteno Ophthalmic Ltd., Dunedin, New Zealand]) to control intraocular pressure (IOP) in various glaucomas.

Methods: Seventeen previously published randomized trials, 1 prospective nonrandomized comparative trial, 1 retrospective case-control study, 2 comprehensive literature reviews, and published English language, noncomparative case series and case reports were reviewed and graded for methodologic quality.

Results: Aqueous shunts are used primarily after failure of medical, laser, and conventional filtering surgery to treat glaucoma and have been successful in controlling IOP in a variety of glaucomas. The principal long-term complication of anterior chamber tubes is corneal endothelial failure. The most shunt-specific delayed complication is erosion of the tube through overlying conjunctiva. There is a low incidence of this occurring with all shunts currently available, and it occurs most frequently within a few millimeters of the corneoscleral junction after anterior chamber insertion. Erosion of the equatorial plate through the conjunctival surface occurs less frequently. Clinical failure of the various devices over time occurs at a rate of approximately 10% per year, which is approximately the same as the failure rate for trabeculectomy.

Conclusions: Based on level I evidence, aqueous shunts seem to have benefits (IOP control, duration of benefit) comparable with those of trabeculectomy in the management of complex glaucomas (phakic or pseudophakic eyes after prior failed trabeculectomies). Level I evidence indicates that there are no advantages to the adjunctive use of antifibrotic agents or systemic corticosteroids with currently available shunts. Too few high-quality direct comparisons of various available shunts have been published to assess the relative efficacy or complication rates of specific devices beyond the implication that larger-surface-area explants provide more enduring and better IOP control. Long-term follow-up and comparative studies are encouraged. *Ophthalmology* 2008;115:1089–1098 © 2008 by the American Academy of Ophthalmology.

The American Academy of Ophthalmology prepares Ophthalmic Technology Assessments to evaluate new and existing procedures, drugs, and diagnostic and screening tests. The goal of an Ophthalmic Technology Assessment is to evaluate the published peer-reviewed literature to help refine the important questions to be answered by future in-

vestigations and to define what is well established. After appropriate review by all contributors, including legal counsel, assessments are submitted to the Academy's Board of Trustees for consideration as official Academy statements. The purpose of this assessment is to provide an evidence-based summary of clinically relevant information about commercially available aqueous shunts.

Originally received: February 27, 2008.

Accepted: March 18, 2008.

Manuscript no. 2008-262.

Financial disclosures of the authors are listed in the appendix.

Prepared by the Ophthalmic Technology Assessment Committee Glaucoma Panel and approved by the American Academy of Ophthalmology's Board of Trustees November 9, 2007.

Funded without commercial support by the American Academy of Ophthalmology.

Background

Aqueous shunts are drainage devices that are used to control intraocular pressure (IOP) in the management of glaucoma. *Aqueous shunt* is the term preferred by the

Table 1. Properties of Commercially Available Aqueous Shunts

	Ahmed	Baerveldt	Krupin	Molteno
No. of models	12	3	1	6
One surface (mm ²)	96–364	250; 350	180	133–265
Explant material	Polypropylene or silicone-rubber	Barium impregnated silicone-rubber	Silastic (silicone rubber)	Polypropylene
Pediatric version	Yes	No	No	Yes
Double plate	Yes	No	No	Yes
Single plate (1-quadrant surgery)	Yes	Yes	Yes	Yes
Valve/flow restriction	Yes	No	Yes	Yes (only with ridged versions or cup in Molteno 3)
Pars plana modification	Yes (pars plana clip)	Yes (Hoffman elbow)	No	No
Shunt tube material (inner diameter)	Silicone (300 μm)	Silicone (300 μm)	Silicone (300 μm)	Silicone (300 μm)

Sources: Ahmed Glaucoma Valve (New World Medical, Inc., Rancho Cucamonga, CA), <http://www.admedvalve.com>; Baerveldt Glaucoma Implant (Advanced Medical Optics, Inc., Santa Ana, CA), <http://www.baerveldt.com>; Krupin (Hood Laboratories, Pembroke, MA), <http://www.hoodlabs.com>; Molteno (Molteno Ophthalmic Ltd., Dunedin, New Zealand), <http://www.molteno.com>.

American National Standards Institute¹ to describe glaucoma drainage devices, which are also referred to as *tube implants*, *tube shunts*, and *setons*. Aqueous shunts have evolved over more than 100 years, and a range of materials have been used to accomplish artificial translimbal or transscleral drainage of aqueous humor.^{2–6} A Cochrane Systematic Review of published randomized controlled trials (RCTs) dealing with various aspects of aqueous shunts was published in 2006.⁷ To the authors' knowledge, as of October 2007, only 1 additional RCT on shunts has been reported since the Cochrane Review was published.^{8–10} Continued clinical interest in shunts is reflected by the publication of 30 to 60 new reports per year, most describing retrospective, noncomparative case series; nonrandomized comparative studies; case-control studies; individual case reports; and reviews.

Most of the shunts in recent successful widespread clinical use (Ahmed [New World Medical, Inc., Rancho Cucamonga, CA], Baerveldt [Advanced Medical Optics, Inc., Santa Ana, CA], Krupin [Eagle Vision, Inc., Memphis, TN], Molteno [Molteno Ophthalmic Ltd., Dunedin, New Zealand]) follow the same biological principles.^{11,12} These devices include an explant plate that, when encapsulated, creates a potential space into which aqueous can drain via a connecting silicone-rubber tube. The explant plates are constructed from materials (polypropylene or silicone rubber) to which fibroblasts cannot adhere tightly. They have identical silicone-rubber tubes with an outside diameter of approximately 600 μm and an inside diameter of approximately 300 μm that connect the explant plate to the anterior chamber or vitreous cavity. Table 1 lists the properties of 4 commercially available shunts. The primary tube–plate junction in all 4 devices includes a rim through which the tube empties onto the explant plate surface to ensure substantial physical separation of the posterior tube orifice from the eventual encapsulation of the device by fibrous tissue after aqueous flow begins. Devices differ depending on explant surface areas, shape, plate thickness, the presence or absence of a valve, and details of surgical installation. Three

devices (Ahmed, Baerveldt, Molteno) can be obtained with different explant surface areas according to surgeon choice (Table 1).

Incorporation of a valve or flow restrictor in aqueous shunts, in theory, should reduce the risk of immediate postoperative hypotony common to nonvalved devices when placed without temporary tube ligation. However, immediate postoperative hypotony also may occur for other reasons, including leaking around the tube as it crosses the sclera or a postoperative decrease in aqueous production. Valves or flow restrictors between aqueous spaces and the explant surface are assumed to be superfluous as soon as the capsule around the explant plate is formed and has matured, but this concept recently has been challenged in bench modeling experiments.¹³ A mechanical valve or flow restrictor that limits aqueous outflow logically would increase the risk of obstruction if intraocular bleeding or inflammation and a fibrinous reaction occur after installation.

Experimental studies, including microperfusion flow experiments in monkeys and rabbits, have demonstrated that the capsule around the explant provides the primary resistance to aqueous outflow through aqueous shunts.^{11,12} The standard tube contributes no measurable resistance to outflow, with physiologic perfusion flow rates of 2 to 4 $\mu\text{l}/\text{minute}$.^{11,12} Explant size (square millimeters) has been shown clinically¹⁴ and experimentally^{11,12} to correlate with the amount of drainage capacity and potential lowering of IOP. Capsule thickness also correlates in experimental studies (rabbits) with capsule hydraulic conductivity (flow in microliters per minute per millimeter of mercury per square millimeter).¹⁵

Aqueous moves through the capsule into surrounding tissues by simple passive diffusion, demonstrated by using horseradish peroxidase and latex particles as markers of flow.^{11,12} In monkey experiments, latex particles with diameters as large as 1.0 μm diffused rapidly though mature capsules around Molteno implants into surrounding orbital tissues.¹¹ In human specimens in which blood had reached

Review: Aqueous shunts for glaucoma
 Comparison: 01 Ahmed implant versus trabeculectomy
 Outcome: 01 Mean intraocular pressure at 11 to 13 months follow up

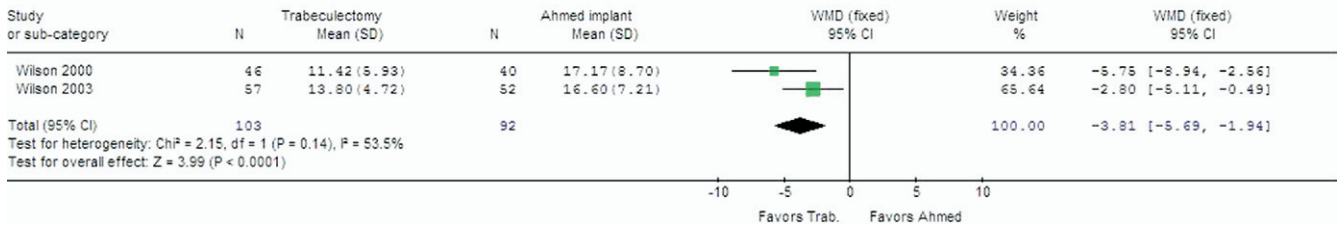


Figure 1. Forest plot of meta-analysis of Wilson 2000 and Wilson 2003 studies comparing trabeculectomy with and without mitomycin C to Ahmed implants. Note: In the Cochrane Review, the number of patients in Wilson 2003 was reduced from 58 to 57 due to concerns about loss to follow-up. Reprinted with permission from Minckler DS, Vedula SS, Li TJ, et al. Aqueous shunts for glaucoma. Cochrane Database Syst Rev 2006; (2): CD004918. Copyright Cochrane Collaboration.

the filtering bleb around the explant, fragments of red cells (± 4 to $5 \mu\text{m}$) were found permeating the capsule wall, indicating that relatively large particles can move through the structure. Transmission electron microscopy of capsule walls after perfusion with horseradish peroxidase demonstrated percolation of the marker between bundles of collagen.¹¹ Case reports indicate that intraocular silicone oil can reach the subconjunctival tissues and incite inflammation after Ahmed implantation and even after previously placed Ahmed or Baerveldt devices would already be well encapsulated.^{16–18}

Conjunctival microcysts are not present over the filtering bleb around explants, which suggests little or no transconjunctival flow, unlike with typical perilimbal trabeculectomy blebs. Generally, the IOP will settle at higher levels (approximately 18 mmHg) than after standard trabeculectomy (14–16 mmHg) or after trabeculectomy with 5-fluorouracil or mitomycin C (8–10 mmHg). In the recently published Tube vs Trabeculectomy (TVT) Study, however, mean IOPs were equivalent at 1 year to either a 350-mm² Baerveldt shunt (12.4 ± 3.9 mmHg) or trabeculectomy with mitomycin C (12.7 ± 5.8 mmHg; $P = 0.73$).⁹ Flow in non-valved shunts is bidirectional, correlating with the ocular pulse, clearly visible by slit-lamp biomicroscopy when fibrin strands attached to the tube tip move in both directions synchronously with the ocular pulse. Clearance of aqueous from the capsule or from pericapsular tissues is presumed to occur primarily via venous capillaries.¹¹ Lymphatics, which some authorities think are not present in orbital tissues, probably play a minor role, if any, in aqueous clearance out of shunt blebs.

If a very low IOP goal range is desirable, an aqueous shunt may be a poor choice for IOP control. However, large-surface-area-shunts rarely may be associated with chronic hypotony, even after all topical medications are discontinued. The Baerveldt devices (250 or 350 mm²) or the silicone versions of the Ahmed and the Krupin devices can be reduced in size surgically after exposure in situ to decrease the explant surface area, resulting in stable higher physiologically acceptable IOP (Minckler D, personal communication).

Experimental evidence suggests that the diameter (geometry) of the filtering fluid space (bleb around the explant)

may play an important role in how encapsulation evolves and how effectively the capsule can drain aqueous. Thinner capsules in theory facilitate higher outflow (greater hydraulic conductivity).¹⁹

Biomaterials research is ongoing, although now the research typically is protected by patent concerns from early disclosure, and it will no doubt lead to improved aqueous shunt design and performance.²⁰ A nonrandomized comparative trial comparing silicone with polypropylene Ahmed devices concluded that the newer silicone version had favorable IOPs at 3 months compared with the older polypropylene device.²¹ Future materials may permit manufacturing adjustments to regulate aqueous flow at IOPs that are ideal for the individual patient's pressure-range goal.

Questions for the Assessment

1. How do aqueous shunts compare with trabeculectomy for IOP control and duration of benefit?
2. How does explant surface area relate to long-term IOP control?
3. What are the indications for aqueous shunts as surgical management options in glaucoma?
4. Is there a role for antifibrotic agents as adjuncts to aqueous shunt installation?
5. Is there evidence supporting the use of systemic corticosteroids or nonsteroidal anti-inflammatory drugs (NSAIDs) as adjuncts to aqueous shunt installation and long-term function?
6. What are the relative advantages and disadvantages of valved and nonvalved shunts?
7. What are the principal complications of aqueous shunts?

Description of Evidence

Literature searches were conducted for the years 2005 through 2007 in the Cochrane Library and in PubMed

Table 2. Published Randomized Controlled Trials in Which at Least 1 Arm of the Study Involved an Aqueous Shunt

First Author (yr)	Main Issue Studied	No.	Main Outcome	Comments	Level of Evidence
Heuer ¹ (1992)	Double-plate Molteno vs. single-plate	66/66	IOP	Statistically significantly in favor of double-plate in subgroup "qualified success" taking medication	I
Smith ² (1992)	Schocket vs. double-plate Molteno	21/19	IOP	Nonstatistically significant difference in favor of Schocket	II
Wilson ³ (1992)	Schocket vs. double-plate Molteno	-/134	IOP	Statistically significant difference in favor of Molteno	I
Lloyd ⁴ (1994)	500-mm ² Baerveldt vs. 350-mm ² Baerveldt	36/37 (500/350)	IOP	No difference, but larger implant required fewer medications	I
Gerber ⁵ (1997)	Pressure-ridge double-plate Molteno vs. standard double-plate Molteno	15/15	IOP	Inadequate data to analyze; 12-week study	II
Cantor ⁶ (1998)	Double-plate Molteno with pressure ridge + MMC vs. balanced salt solution	12/13	IOP	No statistically significant difference in IOP outcome between groups	II
Britt ⁷ (1999)	500-mm ² Baerveldt vs. 350-mm ² Baerveldt	50/53 (500/350)	IOP	No IOP differences, but 350 considered clinically more successful over 5 years of follow-up	I
Valimaki ⁸ (1999)	Single-plate Molteno with or without postoperative oral corticosteroids	11/11	IOP	No statistically significant differences between groups	II
Wilson ⁹ (2000)	Ahmed vs. trabeculectomy in previously operated eyes	55/62	IOP	Favors trabeculectomy	I
Kee ¹⁰ (2001)	Ahmed with or without partial tube ligation	16/16	IOP	No difference between groups	II
Duan ¹¹ (2003)	Hunan (gel) implant with MMC vs. Hunan without MMC	65/94	IOP	Inadequate data; loss to follow-up. Included ultrasound and claimed larger blebs with MMC	II
Susanna ¹² (2003)	Ahmed with or without partial Tenon's resection	45/47	IOP	No statistically significant difference between groups	II
Wilson ¹³ (2003)	Ahmed vs. trabeculectomy as initial surgery	59/64	IOP	Favors trabeculectomy	I
Costa ¹⁴ (2004)	Ahmed with MMC vs. Ahmed without MMC	34/26	IOP	Nonstatistically significant difference favoring MMC use	I
Hwang ¹⁵ (2004)	Ahmed with or without surface area expansion with pericardial patch	10/10	IOP	No benefit to surface area expansion (18% bilateral randomization)	II
Lima ¹⁶ (2004)	Ahmed vs. ECP	34/34	IOP	Nonstatistically significant difference favoring ECP	I
Gedde ¹⁷ (2007)	350-mm ² Baerveldt vs. trabeculectomy with MMC	107/105	Complications	Statistically significantly more complications with trabeculectomy at 1-year follow-up; $P < 0.001$	I
Gedde ¹⁸ (2007)	350-mm ² Baerveldt vs. trabeculectomy with MMC	107/105	IOP and number of medications	No difference in IOP between groups ($P = 0.73$); more medications in tube group ($P < 0.001$)	I

ECP = endocyclophotocoagulation; IOP = intraocular pressure; MMC = mitomycin C.

¹Heuer DK, Lloyd MA, Abrams DA, et al. Which is better? One or two? A randomized clinical trial of single-plate versus double-plate Molteno implantation for glaucomas in aphakia and pseudophakia. *Ophthalmology* 1992;99:1512-9.

²Smith MF, Sherwood MB, McGorray SP. Comparison of the double-plate Molteno drainage implant with the Schocket procedure. *Arch Ophthalmol* 1992;110:1246-50.

³Wilson RP, Cantor L, Katz LJ, et al. Aqueous shunts: Molteno versus Schocket. *Ophthalmology* 1992;99:672-8.

⁴Lloyd MA, Baerveldt G, Fellenbaum PS, et al. Intermediate-term results of a randomized clinical trial of the 350- versus the 500-mm² Baerveldt implant. *Ophthalmology* 1994;101:1456-64.

⁵Gerber SL, Cantor LB, Sponsel WE. A comparison of postoperative complications from pressure-ridge Molteno implants versus Molteno implants with suture ligation. *Ophthalmic Surg Lasers* 1997;28:905-10.

⁶Cantor L, Burgoyne J, Sanders S, et al. The effect of mitomycin C on Molteno implant surgery: a 1-year randomized, masked, prospective study. *J Glaucoma* 1998;7:240-6.

⁷Britt MT, LaBree LD, Lloyd MA, et al. Randomized clinical trial of the 350-mm² versus the 500-mm² Baerveldt implant: longer term results: is bigger better? *Ophthalmology* 1999;106:2312-8.

⁸Valimaki J, Airaksinen PJ, Tuulonen A, Risteli J. Postoperative systemic corticosteroid treatment and Molteno implant surgery: a randomized clinical trial. *Acta Ophthalmol Scand* 1999;77:50-6.

⁹Wilson MR, Mendis U, Smith SD, Paliwal A. Ahmed glaucoma valve implant vs trabeculectomy in the surgical treatment of glaucoma: a randomized clinical trial. *Am J Ophthalmol* 2000;130:267-73.

¹⁰Kee C. Prevention of early postoperative hypotony by partial ligation of silicone tube in Ahmed glaucoma valve implantation. *J Glaucoma* 2001;10:466-9.

¹¹Duan X, Jiang Y, Qing G. Long-term follow-up study on Hunan aqueous drainage implantation combined with mitomycin C for refractory glaucoma [in Chinese]. *Yan Ke Xue Bao* 2003;19:81-5.

Table 2. (Continued)

¹² Susanna R Jr. Latin American Glaucoma Society Investigators. Partial Tenon's capsule resection with adjunctive mitomycin C in Ahmed glaucoma valve implant surgery. <i>Br J Ophthalmol</i> 2003;87:994–8.
¹³ Wilson MR, Mendis U, Paliwal A, Haynatzka V. Long-term follow-up of primary glaucoma surgery with Ahmed glaucoma valve implant versus trabeculectomy. <i>Am J Ophthalmol</i> 2003;136:464–70.
¹⁴ Costa VP, Azuara-Blanco A, Netland PA, et al. Efficacy and safety of adjunctive mitomycin C during Ahmed glaucoma valve implantation: a prospective randomized clinical trial. <i>Ophthalmology</i> 2004;111:1071–6.
¹⁵ Hwang JM, Kee C. The effect of surface area expansion with pericardial membrane (preclude) in Ahmed glaucoma valve implant surgery. <i>J Glaucoma</i> 2004;13:335–9.
¹⁶ Lima FE, Magacho L, Carvalho DM, et al. A prospective, comparative study between endoscopic cyclophotocoagulation and the Ahmed drainage implant in refractory glaucoma. <i>J Glaucoma</i> 2004;13:233–7.
¹⁷ Gedde SJ, Herndon LW, Brandt JD, et al. Tube Versus Trabeculectomy Study Group. Surgical complications in the Tube Versus Trabeculectomy Study during the first year of follow-up. <i>Am J Ophthalmol</i> 2007;143:23–31.
¹⁸ Gedde SJ, Schiffman JC, Feuer WJ, et al. Tube Versus Trabeculectomy Study Group. Treatment outcomes in the tube versus trabeculectomy study after one year of follow-up. <i>Am J Ophthalmol</i> 2007;143:9–22.

(limited to English language) using combinations of the MeSH terms *glaucoma*, *IOP*, *glaucoma drainage implant*, *aqueous shunts*, *glaucoma drainage tube*, *glaucoma drainage device*, *glaucoma device*, *drainage tube*, and *glaucoma implant*. The first author reviewed the searches and identified 1 RCT (Gedde TVT study^{8–10}) that had not been included in the Cochrane Review of aqueous shunts.⁷ In addition, 1 prospective nonrandomized comparative trial, 1 retrospective case-control study, 2 comprehensive literature reviews, and 5 noncomparative case series were identified for inclusion based on their relevance to the assessment questions.

Cochrane Systematic Reviews primarily report RCT data, although some reviews include nonrandomized studies. Cited papers are reviewed in detail with special attention to types of bias likely to occur within randomized trials. Detailed analyses include the method of randomization, equality of study groups, length and completeness of follow-up, and reasons for loss to follow-up and intention-to-treat versus as-treated analysis. In Cochrane Reviews, numerical grading is not provided in deference to details of the methodology.

For this assessment, the methodologist used the following rating scale to assess the level of evidence provided. A level I rating was assigned to well-designed and well-conducted randomized clinical trials; a level II rating was assigned to well-designed case-control and cohort studies; and a level III rating was assigned to case series, case reports, and poor-quality case-control or cohort studies.

Published Results

Systematic reviews of aqueous shunts published subsequent to 2005 have discussed the application, indication, efficacy, and complications of these devices for various types of glaucoma based on analysis of published literature.^{3,22} A comprehensive discussion of the management of neovascular glaucoma, including the use of aqueous shunts, also has been published.²³

As part of the Cochrane Review on aqueous shunts, a metaanalysis of results from 2 studies by Wilson et al^{24,25} indicated that trabeculectomy with and without mitomy-

cin C provided better IOP outcomes over a 1-year follow-up period than the Ahmed implant (Fig 1).⁷ However, the results of the recent RCT by Gedde et al^{8–10} indicate equivalent IOP outcomes for 350-mm² Baerveldt shunts and trabeculectomies with mitomycin C at 1 year and reported fewer complications but more adjunctive medications in the shunt group. Although the overall number of complications was greater in the trabeculectomy with mitomycin C group, there were no clear differences in the types of complications between groups. This made it difficult to conclude that one procedure was safer than the other. Table 2 provides details of 17 RCTs of aqueous shunts. The studies published before 2005 were included in the Cochrane Review of aqueous shunts.⁷

Ishida et al²¹ performed a prospective, nonrandomized study comparing the polypropylene and silicone versions of the Ahmed single-plate implant. They concluded that the newer silicone version has advantages in terms of efficacy (fewer complications and better IOP reduction).²¹ A previous retrospective, comparative study reached similar conclusions.²⁶

In what they describe as a case-controlled comparison study, Syed et al²⁷ concluded that the single-plate Ahmed device and the 350-mm² Baerveldt shunt provided similar IOP control at 1-year of follow-up. Tsai et al²⁸ retrospectively compared Ahmed (n = 48) and Baerveldt (n = 70) shunts and included survival curves to 48 months. Their Baerveldt group included a mixture of 20 implants of 250 mm² and 50 implants of 350 mm². They concluded that the IOP outcomes of Ahmed and Baerveldt devices were comparable, except that there was a higher risk of hypotony with Baerveldt implantation and that the Ahmed patient group required more adjunctive medications and higher rates of additional glaucoma surgery.

In a case-control study by Ishida and Netland,²⁹ patients of African descent had a greater risk of failure with Ahmed implants than patients of European descent in a follow-up of 2.5 and 2.3 years, respectively.

WuDunn et al³⁰ reported a series of 108 eyes treated with the 250-mm² Baerveldt device with a mean follow-up of 22.8 months and a 79% success rate (IOP >6 mmHg or <21 mmHg with or without medications) at 24 months (n = 61). De Guzman et al³¹ reported a series of 33 cases treated

Review: Aqueous shunts for glaucoma updates
 Comparison: 01 Tube implant versus trabeculectomy
 Outcome: 01 Mean intraocular pressure at 11 to 13 months follow up

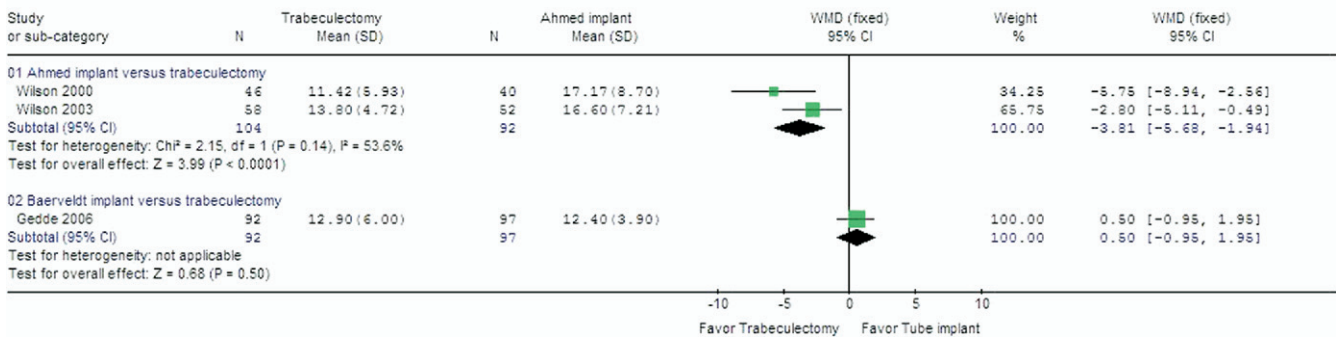


Figure 2. Meta-analysis comparing IOP outcomes for Wilson 2000 and Wilson 2003 as initially reported (Ahmed vs trabeculectomy) with Gedde 2007 (Baerveldt vs trabeculectomy). Courtesy of Tianjing Li, Cochrane Eye and Vision Group US Project.

by inserting a pars plana Baerveldt device with a 5-year success rate (Kaplan-Meier) of 61.1%. Van Overdam et al³² reported on the use of 350-mm² Baerveldt implants for pediatric glaucomas in a series of 40 patients. These authors found an 80% success rate (IOP <21 mmHg) at a mean follow-up of 32 months, dropping to 44% at 60 months. Every et al³³ studied the long-term outcome of Molteno implants for neovascular glaucoma in 130 patients. They reported IOPs of less than 21 mmHg with success rates at 1, 2, and 5 years of 72%, 60%, and 40%, respectively, with double-plate Molteno implants.

Discussion

1. How do aqueous shunts compare with trabeculectomy for IOP control and duration of benefit?

Published reports, including randomized controlled trials before 2006, generally concluded that IOP outcomes were lower with trabeculectomy than with aqueous shunts. However, only the Ahmed device had been compared in prospective trials with trabeculectomy with or without mitomycin C (see Fig 1).^{7,24,25} The TVT study reported equivalent IOP outcomes at 1 year comparing trabeculectomy with mitomycin C with the Baerveldt 350-mm² device (Fig 2).⁸⁻¹⁰ In the TVT study, the shunt group did require more adjunctive medications over the reported follow-up.⁹ The benefits of shunts seem to be comparable with those of trabeculectomy (with antifibrotic agents), with 5-year success rates of approximately 50% (IOP ≤21 mmHg with or without adjunctive medications) in nonneovascular refractory glaucomas.³⁴ In summary, aqueous shunts are comparable with trabeculectomy for IOP control and duration of benefit (level I evidence).

2. How does explant surface area relate to long-term IOP control?

Comparative outcomes of current shunts remain insufficient to conclude that one device is more effective than another,

but several studies, including a randomized trial, concluded that devices with larger equatorial plates control IOP better than smaller ones.^{7,14} The newer double-plate Ahmed device has been favorably reported in a case series,³⁵ but there are no long-term published data supporting the development and maintenance of a bleb over the accessory plate. In summary, larger explant surface area is related to better IOP control (level I evidence).

3. What are the indications for aqueous shunts as surgical management options for glaucoma?

Aqueous shunts have been generally reserved for use after medications, laser surgery, and standard filtering surgery (trabeculectomy) have failed in phakic, pseudophakic, or aphakic eyes, in eyes with prior multiple surgeries, and in eyes with neovascular glaucomas. However, indications for shunts have broadened, and some ophthalmologists advocate their use as the primary surgical intervention, particularly for selected congenital glaucomas.³⁶⁻³⁸ Shunts seem to have advantages over standard surgery in uveitis-related glaucomas.³⁹ Shunts also have been advocated for selected patients for combined cataract and glaucoma procedures.⁴⁰ In summary, although the primary indication for aqueous shunts is when prior medical or surgical therapy has failed, they may be used as primary surgical therapy for selected conditions such as trauma, chemical burns, or pemphigoid (level III evidence).

4. Is there a role for antifibrotic agents as adjuncts to aqueous shunt installation?

Two of 3 RCTs concluded that antifibrotic agents have no beneficial long-term outcome effect when used with aqueous shunts.^{41,42} Among published RCTs, only the study of Duan et al⁴³ concluded that adjunctive mitomycin C was helpful to promote bleb formation and duration. As pointed out in the Cochrane Review on aqueous shunts, this study had several methodologic flaws.⁷ Thus, there is sufficient level I evidence that demonstrates no

benefit in using antifibrotic agents as adjuncts to aqueous shunt procedures.

5. Is there evidence supporting the use of systemic corticosteroids or NSAIDs as adjuncts to aqueous shunt installation and long-term function?

One RCT reported no benefit from the use of systemic corticosteroids as adjuvant therapy after shunt installation.⁴⁴ There are no reported trials comparing NSAIDs with corticosteroids or comparing the use of NSAIDs with no use of NSAIDs. Thus, there is level I evidence that demonstrates no benefit of systemic corticosteroids as adjuncts to aqueous shunt procedures.

6. What are the relative advantages and disadvantages of valved versus nonvalved shunts?

Valved aqueous shunts do not require 2-stage surgery or temporary ligatures and so have the theoretical advantage of simplified installation. However, essentially all reports of outcomes in large series of valved aqueous shunts include cases of immediate hypotony. Undoubtedly, there is variation in resistance among valved devices, and even temporary ligatures are not always complete, so some immediate flow may occur with either valved or nonvalved devices, resulting in immediate hypotony. Also, leakage around the limbal or scleral opening for the drainage tube may aggravate hypotony with any type of shunt, and surgical trauma may decrease aqueous production. In larger case series, immediate hypotony (presumed to be IOP <4 mmHg) has been reported to be between 12% and 26% for all devices.^{3,22} At present, there are insufficient published data to draw any definitive conclusions about the relative likelihood of early postoperative hypotony with implantation of valved or nonvalved devices.

7. What are the principal complications of aqueous shunts?

The major short-term (up to 5 years after surgery) to medium-term (5–10 years after surgery) complications of aqueous shunt devices include immediate hypotony after surgery; excessive capsule fibrosis and clinical failure; erosion of the tube or plate edge; strabismus; and, very rarely, infection.

Overfiltration may be a postoperative consequence that becomes increasingly problematic over time, particularly in eyes that produce less aqueous as a result of aging and disease. It can be addressed at any time after installation of silicone-rubber shunts (Baerveldt, Krupin, flexible-plate Ahmed) by excising part of the explant plate. Failure of an Ahmed device secondary to intraocular bleeding or inflammation with hemorrhage or fibrin obstruction, usually in the valve chamber, can be managed by removing the valve and reclosing the capsule. Irrigation of the tube in situ, although appealing, is difficult.

Aqueous shunts long have been implanted in phakic, pseudophakic, and aphakic eyes. Cataract progression has not been related specifically to shunts, although direct contact between the tube tip and lens can lead to obvious focal lens opacity. Pars plana tube insertion generally seems preferable, providing that the eye previously has undergone complete vitrectomy. Repositioning a tube from anterior chamber to the vitreous cavity, even years after the original installation, may be advantageous for a variety of reasons, but especially to protect the corneal endothelium after vitrectomy.

One option in the face of clinical failure of a shunt is to add a second device in another quadrant, assuming a single-quadrant device is already in place but is not providing adequate IOP control. The possibilities include inserting a second Ahmed device or a second smaller Baerveldt device or adding an Ahmed single-plate device to an existing Baerveldt, Molteno, or Krupin device. Preferably, the first large device, such as a 350-mm² Baerveldt or Krupin disc, will have been placed in the superior temporal quadrant, leaving space superior nasally, inferior nasally, or inferior temporally for a second device. However, placing shunts inferiorly may be problematic cosmetically in some patients. Upper nasal quadrant placement has been associated with pseudo-Brown's syndrome.⁴⁵

Repair of a lacerated or inadvertently severed primary tube with any of the commonly used devices (Ahmed, Baerveldt, Krupin, Molteno) can be accomplished using a number of techniques or the Tube-Extender (New World Medical, Inc., Rancho Cucamonga, CA). Host reactions to the tubing, although rare, have been documented, and epithelial ingrowth into adult eyes or extension to line the capsule around drainage devices also has been described.⁴⁶ Persistent leak from the conjunctiva adjacent to a tube suggests epithelial ingrowth. If the superior temporal conjunctiva has been damaged extensively by prior surgeries and the fornix has been foreshortened, confusion between aqueous leak and palpebral lobe lacrimal secretions can occur.

Erosion of the tube through host sclera or a patch placed at the time of surgery may occur over a period of weeks to months in some cases. During follow-up examinations, observation of loss of conjunctival capillaries over the tube, usually 1 to 3 mm from the corneoscleral junction, is an indication of impending erosion through the surface. Repatching usually can be accomplished before exposure of the tube by redissection from the posterior aspect of the patch and placement of a new patch, ideally donor-preserved sclera, under intact conjunctiva. If the tube is exposed, often difficult extensive lateral dissection is necessary to achieve sufficient conjunctival mobility to recover a repatched tube. Conjunctival grafts, placement of amniotic membrane, or both may be necessary. Amniotic membrane may be helpful to ensure healing when covering tissues are sparse. As long as the edges of the patch graft can be covered by conjunctiva, healing usually occurs by migration of conjunctival epithelium over the central defect.

Infection, either endophthalmitis or infections associated with grafting materials placed over the tube (donor preserved sclera, pericardium, fascia lata), has been rare with

shunts. Recurrent blebitis after trabeculectomy is a reasonable indication for a shunt installation with trabeculectomy bleb closure as an alternative to the risk of repeat endophthalmitis.

Aqueous misdirection has been reported after shunt installation. Anterior chamber tubes may become buried in and obstructed by the iris, may provoke localized lens opacities when in contact with the lens surface, and may lead to diffuse or localized corneal edema sometimes geographically limited to the tube location. In eyes with preexisting peripheral anterior synechiae, especially those associated with rubeosis, advancing peripheral synechiae may ratchet the tube anteriorly into contact with the endothelium. New imaging techniques such as high-resolution ultrasound or anterior segment optical coherence tomography can visualize anteriorly placed tubes and can identify the obstruction site if they have retracted from the anterior chamber.⁴⁷

The use of shunts in eyes containing silicone oil is controversial, but shunts may offer a desirable alternative to cyclodestruction in such cases. Placing the device tube inferiorly, preferably inferior nasally, may decrease the amount of oil escaping into the space between the explant and surrounding capsule.

In summary, there are several complications of aqueous shunts, including clinical failure associated with excessive capsular fibrosis and erosion of the tube or explant through overlying conjunctiva often requiring explantation. The most problematic long-term consequence of anterior chamber tube placement is accelerated damage to the corneal endothelium over time. It is rare that host-defense reactions to the silicone tube become apparent via keratic precipitates on tube surfaces and lead to tube obstruction.⁴⁸ Complications that can be associated directly with hardware installation, such as tube–corneal touch or erosion of the tube or explant through overlying tissues, are relatively unique to the aqueous shunts discussed in this report, without a comparable incidence of similar complications in standard filtering or laser surgeries. However, the risk of postoperative infection is far less with aqueous shunts than after trabeculectomy with antifibrotic agents.

Conclusions

Based on level I evidence, aqueous shunts offer a valuable alternative to standard filtering surgery or to cyclodestructive therapy for many refractory glaucomas. The failure rate is approximately the same rate for trabeculectomy with adjunctive antifibrotic agents, and in favorable cases, shunts may continue to function to control IOP for more than 2 decades.⁴⁹

Future Research

Future research on aqueous shunts should focus on improving the biocompatibility of materials from which they are

made and design parameters to maximize efficacy and minimize volume displacement, strabismus, and erosion. Continued research on ideal postoperative management to minimize fibrosis in the capsule should help greatly in prolonging IOP benefits. Alternatives to currently available antifibrotic agents may help to minimize capsule thickening. Nanotechnology may help to evolve continual IOP-monitoring devices, perhaps fixed to the explant portion of shunts and valving components that will enable more precise titration of IOP.

References

1. American National Standard for Ophthalmics: Aqueous Shunts for Glaucoma Application. ANSI Z80.27–2001. Merrifield, VA: Optical Laboratories Assoc.; 2001:2.
2. eMedicine from WebMD. Ayyala RS, Hong C. Glaucoma, drainage devices. Last updated: October 31, 2005. Available at: <http://www.emedicine.com/oph/topic754.htm>. Accessed December 18, 2007.
3. Hong CH, Arosemena A, Zurakowski D, Ayyala RS. Glaucoma drainage devices: a systematic literature review and current controversies. *Surv Ophthalmol* 2005;50:48–60.
4. Lim KS, Allan BD, Lloyd AW, et al. Glaucoma drainage devices; past, present, and future. *Br J Ophthalmol* 1998;82:1083–9.
5. Minckler DS. Glaucoma drainage devices, horsehair to silicone. In Van Buskirk EM, Shields MB, eds. 100 Years of Progress in Glaucoma. Philadelphia, PA; Lippincott-Raven; 1997:287–92.
6. Rosenberg LE, Krupin T. Implants in glaucoma surgery. In Ritch R, Shields MB, Krupin T, eds. *The Glaucomas*. 2nd ed. Vol. 3. St. Louis, MO: Mosby; 1996:1783–807.
7. Minckler DS, Vedula SS, Li TJ, et al. Aqueous shunts for glaucoma. *Cochrane Database Syst Rev* 2006;(2):CD004918.
8. Gedde SJ, Herndon LW, Brandt JD, et al. Tube Versus Trabeculectomy Study Group. Surgical complications in the Tube Versus Trabeculectomy Study during the first year of follow-up. *Am J Ophthalmol* 2007;143:23–31.
9. Gedde SJ, Schiffman JC, Feuer WJ, et al. Tube Versus Trabeculectomy Study Group. Treatment outcomes in the tube versus trabeculectomy study after one year of follow-up. *Am J Ophthalmol* 2007;143:9–22.
10. Gedde SJ, Schiffman JC, Feuer WJ, et al. Tube Versus Trabeculectomy Study Group. The Tube Versus Trabeculectomy Study: design and baseline characteristics of study patients. *Am J Ophthalmol* 2005;140:275–87.
11. Minckler DS, Shamma A, Wilcox M, Ogden TE. Experimental studies of aqueous filtration using the Molteno implant. *Trans Am Ophthalmol Soc* 1987;85:368–92.
12. Prata JA Jr, Mermoud A, LaBree L, Minckler DS. In vitro and in vivo flow characteristics of glaucoma drainage implants. *Ophthalmology* 1995;102:894–904.
13. Pan T, Stay MS, Barocas VH, et al. Modeling and characterization of a valved glaucoma drainage device with implications for enhanced therapeutic efficacy. *IEEE Trans Biomed Eng* 2005;52:948–51.
14. Heuer DK, Lloyd MA, Abrams DA, et al. Which is better? One or two? A randomized clinical trial of single-plate versus

- double-plate Molteno implantation for glaucomas in aphakia and pseudophakia. *Ophthalmology* 1992;99:1512–9.
15. Prata JA Jr, Santos RCR, LaBree L, Minckler DS. Surface area of glaucoma implants and perfusion flow rates in rabbit eyes. *Glaucoma* 1995;4:274–80.
 16. Friberg TR, Fanous MM. Migration of intravitreal silicone oil through a Baerveldt tube into the subconjunctival space. *Semin Ophthalmol* 2004;19:107–8.
 17. Nazemi PP, Chong LP, Varma R, Burnstine MA. Migration of intraocular silicone oil into the subconjunctival space and orbit through an Ahmed glaucoma valve. *Am J Ophthalmol* 2001;132:929–31.
 18. Parwar BL, Coleman AL, Small KW. Silicone oil migration through an Ahmed valve. *Retina* 2002;22:657–8.
 19. Wilcox MJ, Barad JP, Wilcox CC, et al. Performance of a new, low-volume, high-surface area aqueous shunt in normal rabbit eyes. *J Glaucoma* 2000;9:74–82.
 20. Lloyd AW, Faragher RG, Denyer SP. Ocular biomaterials and implants. *Biomaterials* 2001;22:769–85.
 21. Ishida K, Netland PA, Costa VP, et al. Comparison of polypropylene and silicone Ahmed glaucoma valves. *Ophthalmology* 2006;113:1320–6.
 22. Ayyala RS, Duarte JL, Sahiner N. Glaucoma drainage devices: state of the art. *Expert Rev Med Devices* 2006;3:509–21.
 23. Sivak-Callcott JA, O'Day DM, Gass JD, Tsai JC. Evidence-based recommendations for the diagnosis and treatment of neovascular glaucoma. *Ophthalmology* 2001;108:1767–76.
 24. Wilson MR, Mendis U, Paliwal A, Haynatzka V. Long-term follow-up of primary glaucoma surgery with Ahmed glaucoma valve implant versus trabeculectomy. *Am J Ophthalmol* 2003;136:464–70.
 25. Wilson MR, Mendis U, Smith SD, Paliwal A. Ahmed glaucoma valve implant vs trabeculectomy in the surgical treatment of glaucoma: a randomized clinical trial. *Am J Ophthalmol* 2000;130:267–73.
 26. Law SK, Nguyen A, Coleman AL, Caprioli J. Comparison of safety and efficacy between silicone and polypropylene Ahmed glaucoma valves in refractory glaucoma. *Ophthalmology* 2005;112:1514–20.
 27. Syed HM, Law SK, Nam SH, et al. Baerveldt-350 implant versus Ahmed valve for refractory glaucoma: a case-controlled comparison. *J Glaucoma* 2004;13:38–45.
 28. Tsai JC, Johnson CC, Kammer JA, Dietrich MS. The Ahmed shunt versus the Baerveldt shunt for refractory glaucoma II: longer-term outcomes from a single surgeon. *Ophthalmology* 2006;113:913–7.
 29. Ishida K, Netland PA. Ahmed glaucoma valve implantation in African American and white patients. *Arch Ophthalmol* 2006;124:800–6.
 30. WuDunn D, Phan AD, Cantor LB, et al. Clinical experience with the Baerveldt 250-mm2 glaucoma implant. *Ophthalmology* 2006;113:766–72.
 31. de Guzman MH, Valencia A, Farinelli AC. Pars plana insertion of glaucoma drainage devices for refractory glaucoma. *Clin Experiment Ophthalmol* 2006;34:102–7.
 32. van Overdam KA, de Faber JT, Lemij HG, de Waard PW. Baerveldt glaucoma implant in paediatric patients. *Br J Ophthalmol* 2006;90:328–32.
 33. Every SG, Molteno AC, Bevin TH, Herbison P. Long-term results of Molteno implant insertion in cases of neovascular glaucoma. *Arch Ophthalmol* 2006;124:355–60.
 34. Fluorouracil Filtering Surgery Study Group. Five-year follow-up of the Fluorouracil Filtering Surgery Study. *Am J Ophthalmol* 1996;121:349–66.
 35. Al-Aswad LA, Netland PA, Bellows AR, et al. Clinical experience with the double-plate Ahmed glaucoma valve. *Am J Ophthalmol* 2006;141:390–1.
 36. Budenz DL, Gedde SJ, Brandt JD, et al. Baerveldt glaucoma implant in the management of refractory childhood glaucomas. *Ophthalmology* 2004;111:2204–10.
 37. Ishida K, Mandal AK, Netland PA. Glaucoma drainage implants in pediatric patients. *Ophthalmol Clin North Am* 2005;18:431–42, vii.
 38. Walton DS, Katsavounidou G. Newborn primary congenital glaucoma: 2005 update. *J Pediatr Ophthalmol Strabismus* 2005;42:333–41.
 39. Broadway DC, Iester M, Schulzer M, Douglas GR. Survival analysis for success of Molteno tube implants. *Br J Ophthalmol* 2001;85:689–95.
 40. Hoffman KB, Feldman RM, Budenz DL, et al. Combined cataract extraction and Baerveldt glaucoma drainage implant: indications and outcomes. *Ophthalmology* 2002;109:1916–20.
 41. Cantor L, Burgoyne J, Sanders S, et al. The effect of mitomycin C on Molteno implant surgery: a 1-year randomized, masked, prospective study. *J Glaucoma* 1998;7:240–6.
 42. Costa VP, Azuara-Blanco A, Netland PA, et al. Efficacy and safety of adjunctive mitomycin C during Ahmed glaucoma valve implantation: a prospective randomized clinical trial. *Ophthalmology* 2004;111:1071–6.
 43. Duan X, Jiang Y, Qing G. Long-term follow-up study on Hunan aqueous drainage implantation combined with mitomycin C for refractory glaucoma [in Chinese]. *Yan Ke Xue Bao* 2003;19:81–5.
 44. Valimaki J, Airaksinen PJ, Tuulonen A, Risteli J. Postoperative systemic corticosteroid treatment and Molteno implant surgery: a randomized clinical trial. *Acta Ophthalmol Scand* 1999;77:50–6.
 45. Prata JA Jr, Minckler DS, Green RL. Pseudo-Brown's syndrome as a complication of glaucoma drainage implant surgery. *Ophthalmic Surg* 1993;24:608–11.
 46. Djodeyre MR, Peralta Calvo J, Abelairas Gomez J. Clinical evaluation and risk factors of time to failure of Ahmed glaucoma valve implant in pediatric patients. *Ophthalmology* 2001;108:614–20.
 47. Memarzadeh F, Li Y, Francis BA, et al. Optical coherence tomography of the anterior segment in secondary glaucoma with corneal opacity after penetrating keratoplasty. *Br J Ophthalmol* 2007;91:189–92.
 48. Fellenbaum PS, Baerveldt G, Minckler DS. Calcification of a Molteno implant. *Glaucoma* 1994;3:81–3.
 49. Ah-Chan JJ, Molteno AC, Bevin TH, Herbison P. Otago Glaucoma Surgery Outcome Study: follow-up of young patients who underwent Molteno implant surgery. *Ophthalmology* 2005;112:2137–42.

Appendix. Financial Disclosures of the Authors for the Years 2006 and 2007

Don S. Minckler, MD, MS	C	Alcon Laboratories, Inc.; Allergan, Inc.; Merck U.S. Human Health; NeoMedix; Pfizer Ophthalmics
Brian A. Francis, MD	C	Lumenis, Inc.; NeoMedix, Inc.; Bioformatix, Inc.
	L	Alcon Laboratories, Inc.; Allergan, Inc.; Lumenis, Inc.; Merck U.S. Human Health
	S	Bio-Tissue, Merck U.S. Human Health
Elizabeth A. Hodapp, MD	N	
Henry D. Jampel, MD, MHS	C, O	Allergan, Inc.
	L	Alcon Laboratories, Inc.
Shan C. Lin, MD	N	
John R. Samples, MD	C	Alcon Laboratories, Inc.; Ista Pharmaceuticals; Merck U.S. Human Health; Refocus Group, Inc.
	L	Alcon Laboratories, Inc.; Ista Pharmaceuticals; IRIDEX; Merck U.S. Human Health
	O	Cascade Biologicals
	S	Allergan, Inc.
Scott D. Smith, MD, MPH	N	
Kuldev Singh, MD, MPH	C	Alcon Laboratories Inc.; Allergan, Inc.; Carl Zeiss Meditec; IRIDEX; Novartis Ophthalmics; Pfizer Ophthalmics; Santen, Inc.

C = consultant/advisor (consultant fee, paid advisory boards, or fees for attending a meeting); E = employee (employed by a commercial entity); L = lecture fees (lecture fees [honoraria], travel fees, or reimbursements when speaking at the invitation of a commercial entity); O = equity owner (equity ownership/stock options of publicly or privately traded firms [excluding mutual funds] with manufacturers of commercial ophthalmic products or commercial ophthalmic services); P = patents/royalty (patents and/or royalties that may be viewed as creating a potential conflict of interest); S = grant support (grant support received); N = none (no financial interest; may be stated when such interests might falsely be suspected).
